

## WHY learn lung ultrasound for COVID-19?

Because experience from the medical community in China and Italy has demonstrated that it helps in 3 key areas:

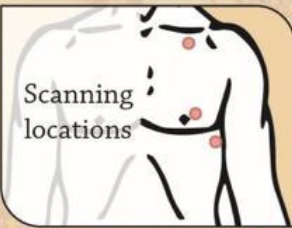
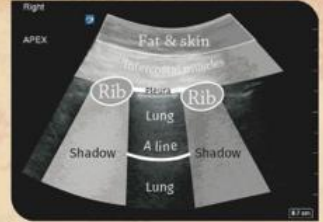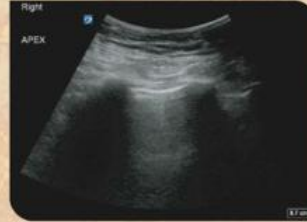1. COVID-19 disease demonstrates a particular pattern of findings on lung ultrasound that can help differentiate it from other causes of acute dyspnoea.
2. Proning of patients is a mainstay of managing ventilated patients with refractory hypoxaemia. The changes responsive to proning can be seen easily on ultrasound.
3. Lung ultrasound can be done at the bedside easily and may well be as sensitive as CT for these things, without the significant logistical issues of obtaining a CT within the context of a pandemic.

## So what does normal lung look like on ultrasound?

It is simple and homogeneous and grey. It sits between ribs when the probe is aligned cephalad-caudad. The ribs cast black shadows. A thin, bright white pleural line with small speckles on it sits atop the lung between the ribs and moves back and forth with each breath.

In much of the lung there is a normal, parallel, white line, an A-line, below the pleura (it will return with disease resolution).

At the base you won't see diaphragm, just lung, then straight to organs.



## Where do I scan the lungs?

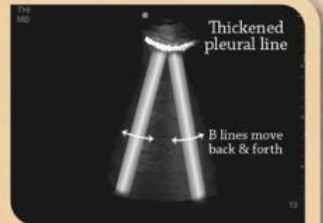
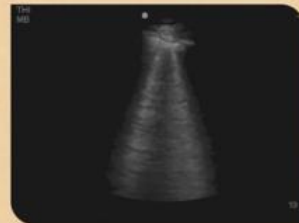
An ultrasound probe is placed to scan at the apex of the lung, baso-anteriorly and postero-laterally (posterior axillary line). This will pick up most pathology, even though some may not make it to the pleura due to aeration.

## What probe do I use?

A low-frequency, curvilinear probe will allow you to see between multiple ribs. Better for obese or oedematous patients. A high-frequency linear probe will show between just one pair of ribs, but with better, shallower, resolution.

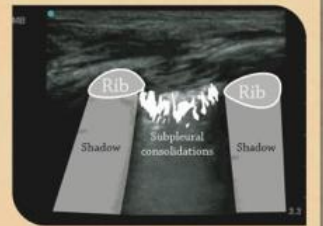
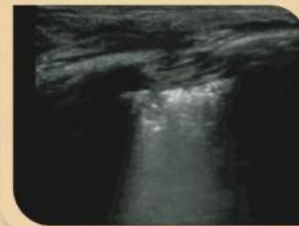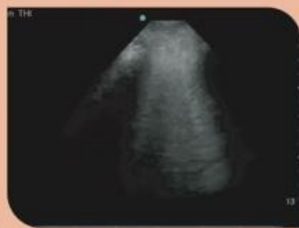
## Early / Mild COVID-19 disease

COVID-19 has a particular pattern in early and mild disease. This involves development of lung ultrasound B lines. These are white lines that arise from the pleura and descend into the lung. They move with breathing. They spread out a little and don't fade as they descend. You may normally have one or two at the lung base. The thin pleural line thickens and develops a lumpy texture to it. Areas with lots of B lines are next to areas with none, causing 'skip lesions'. The pleural line will also thicken causing discrete 'subpleural consolidations'. These features initially appear anteriorly in COVID-19.



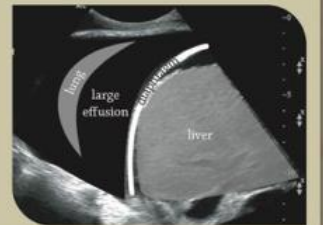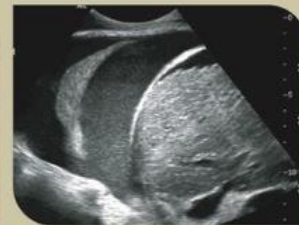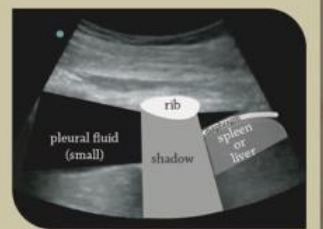
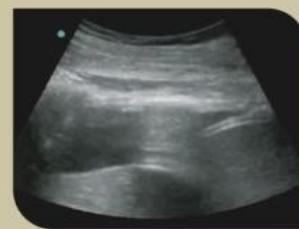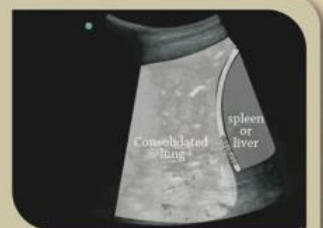
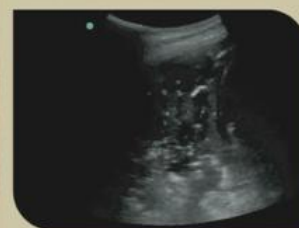## Progressing / Moderate COVID-19 disease

As the disease develops, the B line numbers increase in areas affected, from mainly basal to other areas of the lungs. The B lines also increase in number to become coalescent. In COVID-19 disease this is referred to as **Pattern 1**. With increasing B lines and progressive hypoxaemia fluid balance becomes very important. B lines increase in number as the extravascular lung fluid increases, such as in hypervolaemic states. Fluid removal may be required or increasing the PEEP may improve this. Response would be seen with reducing B line numbers.



## Severe COVID-19 disease

This patient group will likely be already ventilated. The lung will be progressively de-aerated. Alveoli will be full of fluid, secretions or there may be a secondary infection. This lung consolidation can now be easily seen on ultrasound. Changes are mainly postero-basal. It can cause the lung to look like the liver, "hepaticisation". (Scan over the liver to see what this might look like). Pleural effusions may also develop. They form black areas of varying size between the ribs and the lung. In COVID-19 these changes are referred to as **Pattern 2**. These findings suggest proning may be of value. Response would reduce these ultrasound changes toward normality with return of A lines.



## Where to from here?

Governance is importance. Do not over-call interpretations. If in doubt seek expert advice if available or use other imaging modalities. All imaging must be taken in its clinical context.

Ultrasound can be used to diagnose pneumothorax, surgical emphysema, etc., but has been omitted here as it is less relevant to COVID-19.

There is a lot more lung ultrasound you can learn. See [www.ics.ac.uk](http://www.ics.ac.uk) for details of the FUSIC lung ultrasound training programme and other modalities.

## References

Peng, Q., Wang, X. & Zhang, L. Findings of lung ultrasonography of novel corona virus pneumonia during the 2019-2020 epidemic. *Intensive Care Med* (2020). <https://doi.org/10.1007/s00134-020-05996-6>

Huang, Yi and Wang, Sihan and Liu, Yue and Zhang, Yaohui and Zheng, Chuyun and Zheng, Yu and Zhang, Chaoyang and Min, Weli and Zhou, Huihui and Yu, Ming and Hu, Mingjun. A Preliminary Study on the Ultrasonic Manifestations of Prepulmonary Lesions of Non-Critical Novel Coronavirus Pneumonia (COVID-19) (February 26, 2020). <http://dx.doi.org/10.2139/ssrn.3544750>

COVID-19 Critical ultrasound webinar. Chinese Critical Ultrasound Group. Ultrasound Imaging Features & Criteria For Clinical Severity of COVID-19/NCP Cases [https://online.biosonfasteam.com/webcast/mrg202003\\_m.html](https://online.biosonfasteam.com/webcast/mrg202003_m.html)  
Accessed 13/3/2020